

## The comparative study of Hydroquinone and kojic acid in treatment of Melasma in Shadan Institute of Medical Science Teaching Hospital and Research Centre, Himayathsagar road, Hyderabad (Telangana State)

Dr. Sukumar Gajjala<sup>1</sup>, Dr.Syed Yousuf Ali<sup>2</sup>, Dr. Navya chowdary<sup>3</sup>,  
Dr.Singireddy Harshini<sup>4</sup>

<sup>1</sup>Associate professor, Department of Dermatology, Shadan institute of medical science teaching hospital and research centre, Himayathsagar road Hyderabad. (Telangana state).

<sup>2</sup> Professor, Department of Dermatology, Shadan institute of medical science teaching hospital and research centre, Himayathsagar road Hyderabad. (Telangana state).

<sup>3</sup>Post graduate student, Department of Dermatology, Shadan institute of medical science teaching hospital and research centre, Himayathsagar road Hyderabad.(Telangana state).

<sup>4</sup>Post graduate student, Department of Dermatology, Shadan institute of medical science teaching hospital and research centre, Himayathsagar road Hyderabad.(Telangana state).

---

### Abstract:

**Context:** The comparative study of Hydroquinone and kojic acid in treatment of Melasma

**AIM:** Aim of our study of to compare the hydroquinone and kojic acid in treatment of Melasma.

**Setting and design:** The present prospective randomized study was carried out in a tertiary care Hospital, at Hyderabad. This group has 50 patients and comparative study in treatment of Melasma age group 22-30.

**Material and Methods:** on one side of the face we applied hydroquinone and other side kojic acid. The study was conducted for 3 months and results are shown below.

**Statistical Analysis Used:** The average age of the studied cases was 26.91 7.03 and their average duration of disease was 28 years.Kojic acid in our study.

**Key words:** Hydroquinone and Kojic acid.

**Conclusion:** Hydroquinone was more suitable than Kojic acid for the treatment of melasma. Therefore, hydroquinone should be considered in the protocol of treatment for this pigmentation disorder.

---

### I. Introduction:

**Background and aims:** Melasma is one of the most common causes of acquired hypermelanosis of the face. It is characterized by tan-brown macules and patches with a predilection for sun exposed areas, in particular the cheeks, forehead, upper lip, nose, and chin. Women are more affected than men (female to male ratio, 9:1)<sup>1,2</sup>, which generally happens in women between the ages of 25 to 40.

If treatment is not performed in a timely manner, many cosmetic problems can arise. The aim of this study was to compare the effects of kojic acid and hydroquinone 2% creams for the treatment of melasma.

**Methods:** 50 women with epidemic melasma who were referred to the dermatology department of the Shadan Institute of Medical Sciences, Peerancheru, were used in this clinical trial. Each patient had at least two melasma lesions of similar severity and size on both sides of the face. For each patient, kojic acid cream on one side of the face and hydroquinone 2% cream on the other side of the face were prescribed. The researchers assessed the rate of improvement over a three month period.

**Results:** For both applications, a positive response of 2% for kojic acid treatment and 2% for hydroquinone treatment were seen one month after beginning the treatment. After two months, a positive response of 24% for kojic acid and 22% for hydroquinone was observed. The differences were not statistically significant between two groups after 2 months, but statistical significance was seen after 3 months, with positive responses of 30% for kojic acid and 58% for hydroquinone.

Melasma is an acquired increase in skin pigmentation on face and is found mostly in women, often as a physiological change due to pregnancy]. Endocrine mechanisms appear to be involved in its causation, as 50%-70% of pregnant women experience melasma . One of the important causes of melasma is the use of compound contraceptive pills, which results in hyperpigmentation of the face in 8-29% of these cases.

Grimes has also mentioned the use of contraceptive pills as one of the important causes of this disease.<sup>3</sup> Because progesterone and estrogen both stimulate melanogenesis, pregnancy and the use of contraceptive pills are considered as the major factors of hyperpigmentation. Nevertheless, the exact underlying causes of melasma still remain unknown. There also seem to be other factors, such as contact with UV rays, use of anticonvulsive drugs, use of cosmetics, nutritional deficits, liver function disorders, and genetic factors, which are involved in causing melasma. Between 5 to 10 percent of men can also have the same histology and clinical symptoms as do women. However, the role played by hormonal factors in men's melasma is not yet clear Melasma hyperpigmentation is found in all races, but is especially prevalent in Latin and Asian populations, as well as in many tropical areas where there is more exposure to solar rays. Thus, it is less frequently reported in winter . Snatcher et al. and Erbil et al. believe that sunlight is one of the primary causes of melasma.<sup>5</sup>

Hyperpigmentation is most frequently seen on the upper lip, cheeks, forehead, nasal bridge, and chin. It is often brown, is found symmetrically on both sides of the face, and is more obvious in full sunlight . It most commonly appears at the ages of 30-55].

Therapeutic management of melasma includes informing the patient of the prolonged treatment time, evaluating the severity and depth of melasmas lesions, and prescribing a medication. In this regard, various treatment methods, including the use of hydroquinone, tretinoin, isotretinoin, adapalenes, azelaic acid, arbutin, licorice, sodium ascorbyl phosphate (an activated form of vitamin c), mandelic acid, magnesium ascorbyl phosphate, hydroxy acid and kojic acid have all been suggested by clinical research.<sup>8,9</sup> Presently, there are various lightener creams available, the most important of which is hydroquinone cream. This is used at different concentrations, based on severity and depth of melasma, and is the most popular treatment. It is also the most effective material as a local depigmenting agent and is the gold standard for treatment of melasma. Spinal-Perez et al.<sup>10</sup> studied 16 patients suffering from symmetric melasma lesions in Mexico. They used ascorbic acid 5% on one side of the face and hydroquinone cream on the other side for 16 weeks and found that 93% of melasma lesions treated by hydroquinone cream improved, whereas only 62.5% of those treated by ascorbic acid showed improvement. Another highly effective and unique depigmenting agent for melasma treatment is kojic acid cream, which was first discovered by Dr Saito in Japan in 1907 through fermentation of sugar by a kind of fungus.<sup>5,6</sup> Kojic acid has found many applications in esthetics for its whitening effects, fewer side effects, and ability to clear the hyperpigmented lesions of the face and body. It can also prevent the production of melanin through inhibition of the tyrosinase enzyme, which allows the whitening of skin and treatment of acquired hyperpigmentation . The effectiveness of kojic acid in treatment of melasma has been controversial]. Therefore, this research was designed to compare the effects of kojic acid cream and hydroquinone 2% for the treatment of melasma.

## II. Materials and Methods:

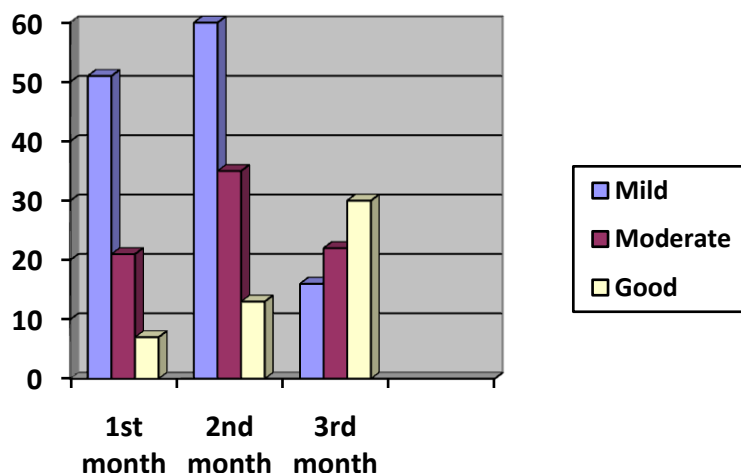
This research was carried out as a clinical trial on 50 non-pregnant women with moderate to severe melasma over a 3 month period at the dermatology department of Shadan institute of medical sciences in 2005. The selected patients had lesions of the same size and severity on both sides of their faces.

The severity of melasma lesions was determined by a specialist, based on their color, size and clinical symptoms. The depth of the lesions was measured with a wood lamp, which was capable of showing the extra melanin in epidermal or dermal layers . Based on the observations with this lamp, melasma lesions were divided into three groups; epidermic, dermic, and mixed . A written agreement was obtained from the University's ethics committee and the departments involved, special questionnaires on the history of melasma, on drug history and on the route of drug usage were completed, and essential training on the study method was provided. Patients were selected from those who had not received any medicine for melasma for two weeks prior to the study.

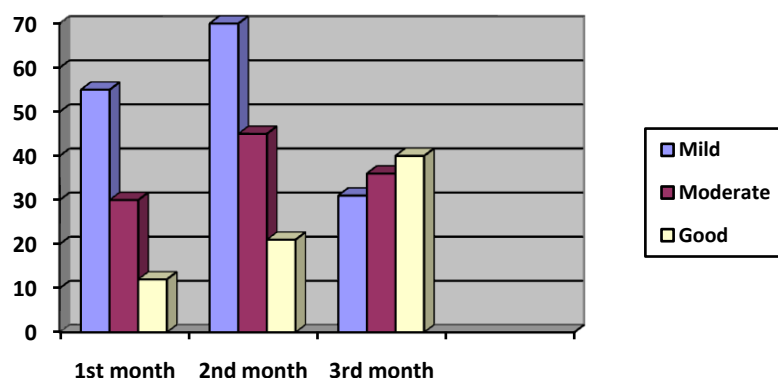
The patients were asked to apply kojic acid 2% to the lesions on the right side of their faces and hydroquinone cream 2% to those on the left, at the same time every night (both creams were made by Sina Co.). The patients were allowed to use Arden sunscreen cream [sun protection factor (SPF) 30] during the day to protect against the ultra-violet effects of sunlight. To prevent the problem of confusing which side was to be treated with which cream, instructions were written down separately for each patient (for instance, melasma lesions on the right cheek were treated with kojic acid, and the ones on left side, with hydroquinone). At the end of each month, patients were referred to the dermatology department and were assessed by a different specialist, who was not informed of the positions of the treated lesions.

Medication	Response	1 <sup>st</sup> month	2 <sup>nd</sup> month	3 <sup>rd</sup> month
Kojic acid	Mild	51%	60%	16%
	Moderate	21%	35%	22%
	good	7%	13%	30%
Hydroquinone 2%	Mild	55%	70%	31%
	Moderate	30%	45%	36%
	Good	12%	21%	40%

KOJIC ACID



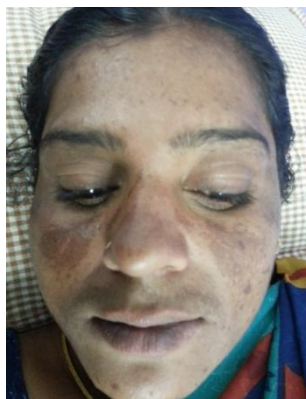HYDROQUINONE 2%



III. Results:

The average age of the studied cases was 26.91 7.03 and their average age of the patient 28 years (25-30). 28% of the patients reported the start of this disease before pregnancy and 72% after it. In 57% of the cases, it has started after taking contraceptive pills and in 69% of these, melasma was further aggravated by pregnancy. The severity of melasma lesions was found to be moderate in 57% and severe in 43% of the patients in this study. In addition, melasma lesions worsened in 58% of patients due to sunlight exposure. The most common positions of melasma lesions were the nose, cheeks, and forehead (33%), nose and cheeks (31%), both cheeks (19%), and nose, cheeks, forehead, chin and upper lip (17%). Treatment with hydroquinone was reported in 67% of the cases (figure 1,2), but none of the patients had experienced the use of kojic acid for the treatment of their melasma.

Medication	Response	1 <sup>st</sup> month	2 <sup>nd</sup> month	3 <sup>rd</sup> month
Kojic acid	Mild	51%	60%	16%
	Moderate	21%	35%	22%
	good	7%	13%	30%
Hydroquinone 2%	Mild	55%	70%	31%
	Moderate	30%	45%	36%
	Good	12%	21%	40%



**Figure 1:** before treatment



**Figure 2:** after treatment

#### **IV. Discussion:**

The treatment of melasma remains a challenge and its results frequently produce the dissatisfaction of the physician and the patient. The anatomopathological and ultra-structural analysis of the skin with melasma, in comparison with the adjacent non-lesioned skin, shows a greater degree of photoaging, larger melanocytes with hyper activity (more dendrocytes), and increase in its number.<sup>7</sup>

At this time, there are a number of different methods for treating melasma. Of the topical treatments, hydroquinone is the most widely used and the most effective. Used at a concentration of 2% it is as effective as at higher concentrations (4 to 6%) and presents lower rates of side effects<sup>7,8</sup> like irritative contact dermatitis and allergy, post inflammatory pigmentation and discoloration of the nails and eyebrows.

Kojic acid local cream 2% is one medication that has recently been seriously considered for the treatment of this disease. Hydroquinone cream is also a commonly used melasma treatment. The results of this study clearly demonstrate a positive effect of kojic acid cream 2% on melasma lesions, with improvements of 10%, 22% and 32%, seen at the end of the first, second and the third month, respectively. In contrast, the positive response to treatment with hydroquinone cream 2% at the end of the first, second and the third month were 7%, 24% and 53%, respectively<sup>7</sup>. Lim et al have also compared the compound effects of kojic acid, hydroquinone 2% and glycolic acid 10% to the therapeutic effects of hydroquinone 2% and glycolic acid 10% compound cream on melasma lesions in China<sup>4</sup>. By the end of 12 weeks of treatment, there was a positive response of 60% on melasma lesions on the right side of face treated by the compound cream containing hydroquinone. Alternatively, melasma lesions on the left side treated by the compound cream without hydroquinone showed a positive response of only 47.5%. In two patients who received a compound cream of three medicines (containing kojic acid), melasma lesions on one side completely disappeared. In another study, Garcia<sup>8</sup> and Fulton compared the effects of two compound creams of glycolic acid and hydroquinone with those of glycolic acid and kojic acid for three months on 39 women heaving melasma. They found that 51% of melasma lesions on both sides showed an equal positive response to the treatment by the two compound creams. Our study, however, provides conclusive evidence that hydroquinone is more effective in treatment of melasma than is kojic acid.

In this regard, Cotellessa et al analyzed the comparative effects of a glycolic acid 50% and kojic acid 10% compound jelly on 20 female patients (group I) and that of trichloroacetic acid 15% jelly on 20 other patients (group II) including 16 women and 4 men<sup>11</sup>. At the end of the study, there was a complete improvement in 42% of patients, relative improvement in 48%, but no improvement in 10% in group I. In group II, 40% of patients gained complete improvement, 50% relative improvement, and 10% no improvement. These results, taken together, indicate a positive effect of both treatments on melasma. The current study further indicates that kojic acid cream is an additional appropriate choice as a melasma treatment.

Hydroquinone cream has been a popular treatment for melasma for many years, it has a number of adverse side effects, including dermal irritation, erythema, rash, pruritis and burning sensation.. In the current research, 53% of patients who had melasma lesions on the left side treated by hydroquinone cream 2% complained about erythema and burning sensation side effects. On the other hand, only 26% of those treated by kojic acid (on the right side of the face) cream did so. This finding agrees with the results of Garcia and Fulton's study<sup>4</sup>, in which erythema and pruritis side effects were observed in 47% of patients treated by glycolic acid and hydroquinone cream, with the severity of the pruritis side effect resulting in 8% of the patients being left out the research. Similar side effects were seen in only 31% of the patients who had used glycolic acid and hydroquinone cream.

### **V. Conclusion:**

Hydroquinone was more suitable than Kojic acid for the treatment of melasma. Therefore, hydroquinone should be considered in the protocol of treatment for this pigmentation disorder.

### **Acknowledgment:**

All authors have neither conflicts of interest nor financial support from pharmaceutical companies.

### **References**

- [1]. Pandya AG. Safety and efficacy of 4% hydroquinone combined with 10% glycolic acid, antioxidants, and sunscreen in the treatment of Melasma. *Int J Dermatol.* 2003;42:966–72.
- [2]. Thappa DM. Melasma (Chloasma): A review with current treatment options. *Indian J Dermatol.* 2004;49:165–76
- [3]. Pearl E, Grimes PE. Melasma: etiologic and therapeutic considerations. *Arch Dermatol* 1995; 13: 145357
- [4]. Erbil H, Sezer E, Tastan B, Arca E, Kurumlu Z. Efficacy and safety of serial glycolic acid peels and a topical regimen in the treatment of recalcitrant melasma. *J Dermatol* 2007; 34: 25-30.
- [5]. Garcia A, Fulton JE., Jr The combination of glycolic acid and hydroquinone or Kojic acid for the treatment of Melasma and related conditions. *Dermatol Surg.* 1996;22:443–7.
- [6]. Lim JT. Treatment of Melasma using Kojic Acid in a gel containing Hydroquinone and Glycolic Acid. *Dermatol Surg.* 1999;25:282–4.
- [7]. Kang WH, Yoon KH, Lee E-S, Kim J, Lee KB, Yim H, SohnS, Im S. Melasma: histopathological characteristics in 56 Korean patients. *Br J Dermatol* 2002;146: 228-37
- [8]. Sanchez IL, Vasquez M. A hydroquinone solution in the treatment of melasma. *Int J Dermatol* 1982;21:55-8.
- [9]. Glenn M, Grimes PE, Pitt E, Chalet M, Kelley AP. Evaluation of clinical and light microscopic effects of various concentrations of hydroquinone. *Clin Res* 1991;39 83A.
- [10]. Espinal-perez LE, Moncada B, Castanedo-cazares JP. A double-blind randomized trial of 5% ascorbic acid vs. 4% hydroquinone in melasma. *Inter J Dermatol* 2004; 43: 604-607
- [11]. Cotellessa C, Peris K, Onorati MT, Fargnoli MC, Chimenti S. The use of chemical peelings in the treatment of different cutaneous hyperpigmentations. *Dermatol Surg.* 1999;25:450–4. Guevara IL,